

# OPEN ACCESS GUIDE TO AUDIOLOGY AND HEARING AIDS FOR OTOLARYNGOLOGISTS



## EARWAX REMOVAL TECHNIQUE

Kate Stephenson, Claude Laurent

The ear is typically a ‘self-cleaning’ organ. The normal migration of keratin from squamous epithelium occurs in an outward direction from the tympanic membrane towards the opening of the external ear canal at an approximate speed of 0.05mm/day.<sup>1</sup> Only the outer portion of the external ear canal contains cerumen-producing glands.

Earwax is a normal protective feature of the external ear canal, possessing cleaning, pH regulating activity, antibacterial and antifungal properties. It is a *water-soluble* mixture of dead skin, hair and cerumen. Earwax may be removed if it causes ear symptoms such as hearing impairment or if it prevents adequate visualisation of the tympanic membrane. A conductive hearing loss may occur if the wax impacts totally, particularly when it apposes the tympanic membrane. The widespread practice of cotton bud (‘Q tip’) insertion into the external auditory canal often leads to displacement and impaction of wax into the deeper portion of the canal. This practice also slows down the transport of debris out of the external ear canal.

### Indications for cleaning the external ear canal

- To permit complete inspection of the external auditory canal and tympanic membrane and to facilitate inspection during pneumatic otoscopy (see chapter: [Pneumatic otoscopy and otoscopy](#))
- Impaired hearing or discomfort. This often occurs if water becomes trapped within the ear canal after bathing, showering or swimming
- Prior to audiological testing
- Prior to hearing aid mould impression taking. All of the wax should be removed prior to taking an ear impression. If this is not done, there is a risk that wax may be pushed deeper into the

canal; wax may also affect the accuracy of the impression

- To prevent a wax blockage in the ear canal with a hearing aid mould. A large accumulation of ear wax can also cause the hearing aid to have feedback, typically presenting as a high-pitched whistling sound
- Ear canal conditions such as different forms of otitis externa
- For removal of foreign bodies (not covered by this chapter). These are found mainly in children and may be difficult to remove without a general anaesthetic. Attempts at “blind” removal and the use of unsuitable instruments may be negligent approaches. Removal of foreign bodies should therefore only be carried out by a specialist with appropriate equipment (such as fine instruments and a head light or otomicroscope), other than the simplest of cases, such foreign bodies that lie in the lateral ear canal and soft, easily-grasped materials

### Methods of external ear canal cleaning

Cleaning the external ear canal or ‘ear toilet’ can be achieved in a number of ways. These can be tailored to the age of the patient, the available equipment and the expertise of the medical professional.

It is important to start by enquiring if the patient has previously undergone ear surgery. The ear should then be inspected with an otoscope and the presence and location of wax or discharge noted (see chapter on otoscopy). If the tympanic membrane is visible, one should check for the presence of a perforation and/or other pathology.

- When performing ear canal examination and cleaning it is best to sit at the

same level as the patient. The use of an adjustable-height stool is advisable.

- Adequate illumination of the ear canal is essential. Options include use of a head light and a head mirror reflecting a static light or use of an otoscope or an otomicroscope. Recently videotoscopes have entered the market and also mobile phone-based otoscopes may come into wider use *e.g.* the CellScope Oto® (Figure 1)



Figure 1: Mobile phone-based otoscope

The commonest otoscopic finding is partial wax obstruction of the ear canal. It may be treated by syringing, instrumental removal or suction under direct vision, as discussed below. The patient should be advised to cease use of any foreign bodies within the ear canal, including cotton buds ('Q tips').

### Wax softeners

There is some evidence that either warm water or drops designed to aid clearance of wax instilled into the ear canal 15 minutes prior to syringing may reduce the syringing time required.<sup>2,3</sup> Current evidence does not conclusively show whether wax softeners alone are effective in clearing wax, or whether one type of softener is more effective than another.<sup>4</sup>

Wax softeners or cerumenolytics can be divided into oil-based, water-based and non-water/non-oil-based preparations (Table 1). Drops may be used in isolation to encourage the dispersal of wax or be used before manual wax removal or syringing. Hydrogen peroxide (3%) may be particularly useful for the dispersal of very hard wax when instilled 15 minutes prior to a cleaning attempt.

The patient should lie with the affected ear uppermost for 5-10 minutes after the drops have been introduced into the ear canal. Repeated digital pressure on the tragus encourages movement of the drops and wax dispersal.

Oil based	Water based	Non-water/non-oil based
Olive oil	Sodium bicarbonate (5-10%)	Carbamide peroxide
Almond oil	Hydrogen peroxide (3%)	Glycerol-combination preparations
Camphor oil	Acetic acid (1-3%)	
Arachis (peanut) oil	Docusate sodium	
Mineral oil	Saline	
	Water	

Table 1: Wax-softening / dispersing drops

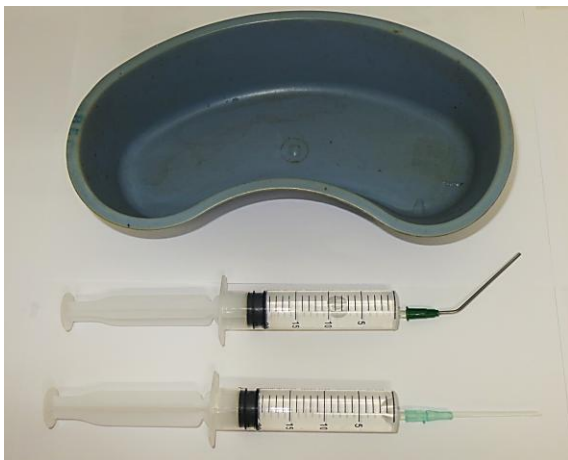### Syringing

This is best performed under direct vision; the use of a head lamp assists in visualisation of the ear canal.


- Pull the pinna gently **upwards and backwards** to straighten the external ear canal and enable better visualisa-

tion. The shape of the canal changes up until the age of 9yrs; in younger children, pull the pinna gently **downwards and backwards**

- Place a kidney-shaped dish under the ear to collect the water overflow
- Fill a large (e.g. 20ml) syringe with a firmly attached metal or plastic cannula with lukewarm water (*Figure 2*). Mechanical irrigators may also be used (*Figure 3*)



*Figure 2: Manual syringing equipment*

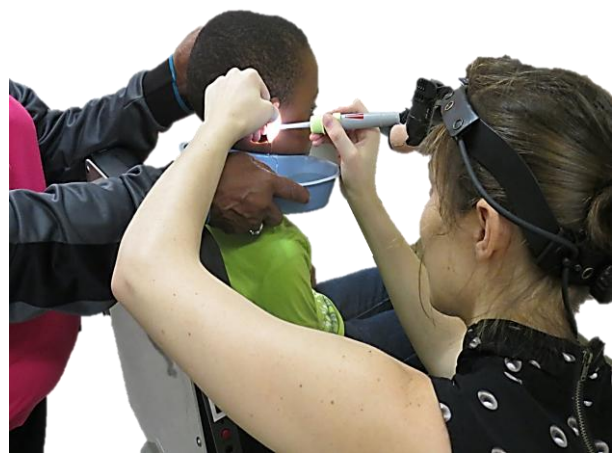

*Figure 3: Example of a mechanical syringing apparatus*

- It is important to ensure that the water is at body temperature (37 °C); otherwise discomfort and vertigo may be induced by stimulation of the labyrinth (caloric effect)

- **Direct the jet of water backward and upward** and not directly at the tympanic membrane. A number of syringe-fuls may be required before the wax is cleared
- Intermittently inspect the canal
- Inspect the expelled water for evidence of the wax

The technique is demonstrated in *Figure 3*.



*Figure 4: Ear syringing*

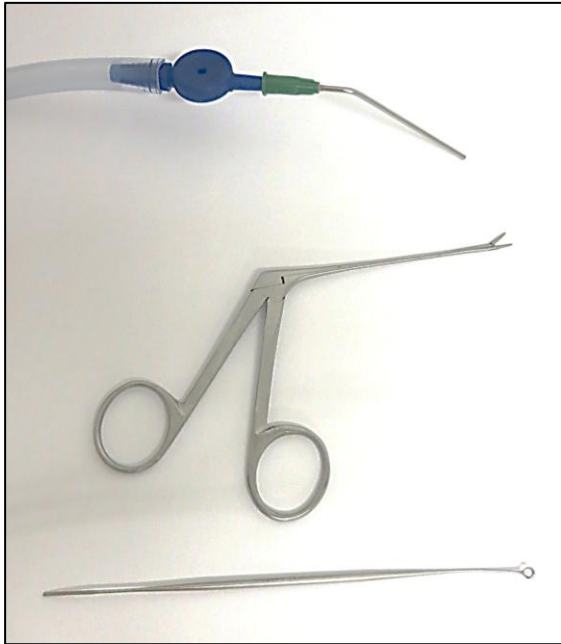
**Syringing is contraindicated** in the presence of **discharge** or if the patient has history of a tympanic membrane **perforation** or previous ear **surgery**. If this is the case, it may be necessary for a specialist to clean the ear canal manually.

**Complications** include pain, development of an otitis externa, and damage to the external ear canal skin or tympanic membrane. Irrigation should be stopped if the patient complains of pain or water draining into the throat.

### **Instrumental removal** (*Figures 5, 6*)

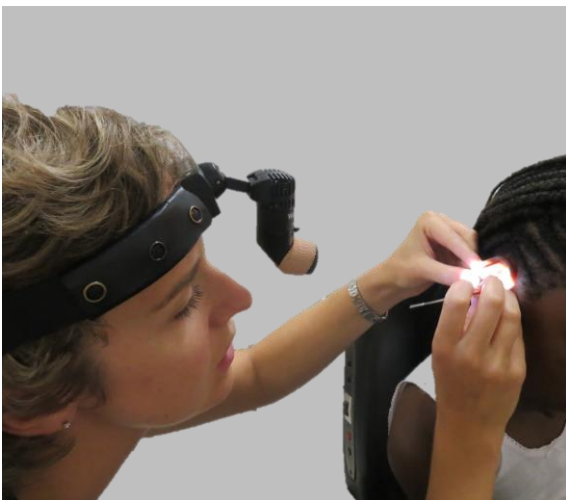Specialised instruments include

- Jobson-Horne probe
- Wax hook / loop
- Crocodile forceps



*Figure 5: Instrumental removal equipment: fine suction tip, crocodile forceps, Jobson-Horne probe*

This is best suited to soft wax that is located close to the external auditory meatus and in the lateral ear canal. Cleaning in this fashion must be performed under direct vision with adequate illumination. This may be achieved by use of a head lamp (*Figure 6*) or an otomicroscope.



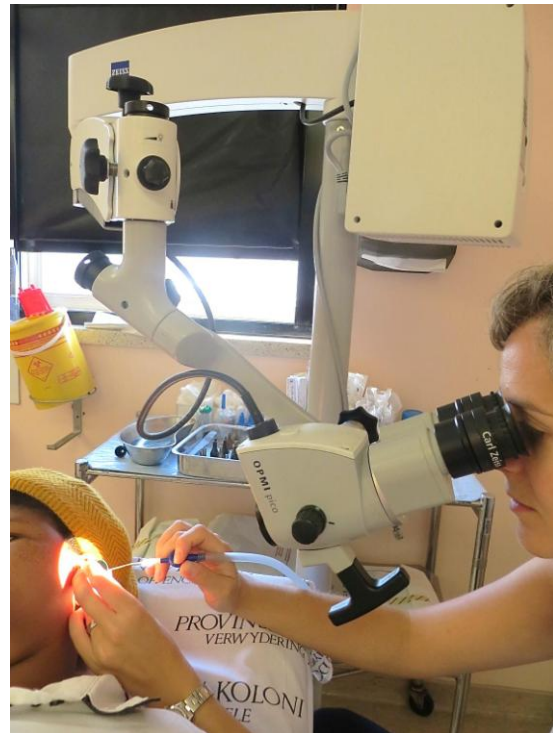*Figure 6: Instrumental wax removal*

The instrument is passed alongside and deep to the wax and drawn carefully

outwards, removing the wax deposit. It is important to avoid contact with the sensitive ear canal otherwise pain and trauma may result. Poor visualization and use of the instrument close to the tympanic membrane may also risk damaging it.

### **Microsuction**

Specialists often prefer otomicroscopic ear toilet as it allows magnification (x6 or x10) and binocular vision. Depth perception is therefore improved and 2-handed working is also permitted. The ear canal can be cleaned with greater precision and reduced patient discomfort whilst the ear canal and tympanic membrane are inspected in detail (*Figure 7*).




*Figure 7: Otomicroscopic ear toilet*

Adequate and safe cleaning of the external ear canal may not be possible in all cases. Children and adults with limited cooperation, such as toddlers and those with mental impairment may require a general anaesthetic for ear toilet. Patients with significant ear pain may also require anaesthesia for effective cleaning.

## Dry mopping

Dry mopping may be performed in a discharging ear but is not appropriate for the cleaning wax or other debris. It should be performed prior to the insertion of eardrops in a discharging ear; patients and families may be instructed to perform this at home.

- Twist a clean piece of cotton wool onto the tip of a suitable carrier, such as an orange stick or a Jobson-Horne probe (*Figure 8*)
- Ensure that the cotton wool adequately covers the end of the stick or probe to prevent injury to the ear canal or tympanic membrane
- Take care to check that the cotton wool is securely attached to the stick so that it does not become detached and remain within the ear canal
- Introduce and gently rotate the ‘mop’ within the ear canal under direct vision
- Repeat this action with clean cotton wool until it is returned clean or the discharge is removed



*Figure 8: Dry mopping is done with cotton wool rolled onto an orange stick*

## Conclusions

Cleaning of the ear canal may be time consuming; more than one method of cleaning may be required and at more than one appointment, with or without the use of wax-softening drops.

Referral to an ear specialist should be considered in patients with a swollen or

painful ear canal (indicates some form of external otitis media), unusual anatomy, such as exostosis or an ear canal stenosis, or a history of tympanic membrane perforation or surgery.

A formal hearing evaluation should also be considered in patients after wax removal, in particular in those with persistent hearing loss after the removal.

In summary, a variety of methods can be used to clean the external ear canal and this may be performed by both specialists and non-specialists. The ability to clean an ear canal may be both useful and satisfying.

## References

1. Alberti PW. Epithelial migration on the tympanic membrane. *J Laryngol Otol.* 1964;78:808-30
2. McCarter DF, Courtney AU, Pollart SM. Cerumen impaction. *Am Fam Physician.* 2007 May 15;75(10):1523-8
3. Roland PS, Smith TL, Schwartz SR et al. Clinical practice guideline: Cerumen impaction. *Otolaryngol Head Neck Surg.* 2008;139:S1-S21 [American Academy of Otolaryngology – Head and Neck Surgery (AAO-HNS) Clinical Practice Guideline]
4. Browning GG. Ear wax. *Clinical Evidence (Online).* 2008 Jan 25;2008 pii: 0504

## Author

Kate Stephenson FCORL(SA), FRCS  
ORL-HNS(Eng.), MMed

Registrar

Division of Otolaryngology

University of Cape Town

Cape Town

South Africa

[drkatestephenson@gmail.com](mailto:drkatestephenson@gmail.com)

### **Co-author and Editor**

Claude Laurent MD, PhD  
Professor in ENT  
ENT Unit  
Department of Clinical Science  
University of Umeå  
Umeå, Sweden  
[claude.laurent@ent.umu.se](mailto:claude.laurent@ent.umu.se)

### **Editor**

De Wet Swanepoel PhD  
Professor  
Department of Communication Pathology  
University of Pretoria  
Pretoria, South Africa  
[dewet.swanepoel@up.ac.za](mailto:dewet.swanepoel@up.ac.za)

### **Editor**

Johan Fagan MBChB, FCORL, MMed  
Professor and Chairman  
Division of Otolaryngology  
University of Cape Town  
Cape Town, South Africa  
[johannes.fagan@uct.ac.za](mailto:johannes.fagan@uct.ac.za)

***OPEN ACCESS GUIDE TO  
AUDIOLOGY & HEARING AIDS  
FOR OTOLARYNGOLOGISTS***

[www.entdev.uct.ac.za](http://www.entdev.uct.ac.za)



The Open Access Atlas of Otolaryngology, Head & Neck Operative Surgery by [Johan Fagan \(Editor\)](mailto:johannes.fagan@uct.ac.za) [johannes.fagan@uct.ac.za](mailto:johannes.fagan@uct.ac.za) is licensed under a [Creative Commons Attribution - Non-Commercial 3.0 Unported License](https://creativecommons.org/licenses/by-nc/3.0/)